



Simultaneous presentation of idiopathic macular and posterior full-thickness retinal holes successfully treated with inverted internal limiting membrane flap technique

Claudio Iovino^{a,b}, Giuseppe Demarinis^a, Filippo Tatti^a, Enrico Peiretti^{a,c,*}

^a Eye Clinic, Department of Surgical Science, University of Cagliari, Cagliari, Italy

^b Eye Clinic, Multidisciplinary Department of Medical, Surgical and Dental Sciences, University of Campania Luigi Vanvitelli, Naples, Italy

^c Clinica Oculistica, San Giovanni di Dio Hospital, Azienda Ospedaliera Universitaria di Cagliari, Cagliari, Italy

ARTICLE INFO

Keywords:

Full thickness macular hole
Inverted flap technique
Posterior retinal hole
Vitreoretinal surgery

ABSTRACT

Purpose: To report an unusual non-iatrogenic case of central macular and posterior full-thickness retinal holes (FTRHs).

Observations: A 60-year-old man presented with a progressive visual loss in the right eye. A complete ophthalmological evaluation including best corrected visual acuity (BCVA) measurement, fundus examination and spectral - domain optical coherence tomography (SD-OCT) was performed.

Fundus examination and SD-OCT confirmed the presence of simultaneous macular and posterior FTRHs. A 25-gauge vitrectomy was performed and the internal limiting membrane (ILM) was grasped and peeled off around the two holes. A fragment of the peeled-off ILM anchored on the FTRHs edges was left and inserted into the gaps.

Closure of both retinal holes was achieved at 1-month, and BCVA improved from 20/630 at baseline to 20/63 at month 3. No intraoperative or postoperative complications were recorded.

Conclusions and Importance: Inverted ILM flap technique represents a good treatment option in this rare non-iatrogenic condition, allowing a good anatomical and functional recovery.

1. Introduction

Idiopathic full-thickness macular hole (FTMH) is a round gap opening at the center of the fovea due to a failure of normal age-related separation of the vitreous cortex from the posterior pole.¹ Paracentral retinal hole is a rare condition usually occurring after macular surgery. Internal limiting membrane (ILM) peeling has been proposed as a possible risk factor for its formation.² The presence of idiopathic and simultaneous macular and posterior full-thickness retinal holes (FTRHs) has never been reported. Nevertheless, there is no consensus about the etiology and treatment strategy of this uncommon condition. We hereby present a rare case of idiopathic macular and posterior full-thickness retinal holes (FTRHs) successfully treated with inverted ILM flap technique.

2. Case-report

A 60-year-old Caucasian male was referred to our Retina Service Unit for

a progressive visual loss in the right eye (RE). The patient did not report any previous ocular surgery or ocular and head trauma history. A complete ophthalmological examination was performed including anterior segment slit-lamp examination, intraocular pressure (IOP) measured by Goldman applanation tonometer, fundus examination, spectral-domain optical coherence tomography (SD-OCT, Heidelberg Engineering, Germany). Snellen best-corrected visual acuity (BCVA) was recorded.

Written informed consent to publish these case and accompanying images was obtained from the patient.

Anterior segment slit-lamp examination showed nuclear sclerosis of the lens in both eyes and IOP was 16 mmHg.

BCVA was 20/630 in the RE and 20/20 in the left eye (LE).

Fundus examination showed a stage 4 FTMH with a second posterior FTRH within the infero-temporal vascular arcade in the right eye (Fig. 1). LE fundus examination was unremarkable.

Radial SD-OCT scan confirmed in the RE the presence of the two FTRHs with intraretinal hyporeflexive cystoid spaces. The distance of

* Corresponding author. Eye Clinic, University of Cagliari, Via Ospedale 48, 09124, Cagliari, Italy.

E-mail addresses: enripei@hotmail.com, epeiretti@unica.it (E. Peiretti).

<https://doi.org/10.1016/j.ajoc.2021.101070>

Received 28 September 2020; Received in revised form 17 January 2021; Accepted 5 March 2021

Available online 10 March 2021

2451-9936/© 2021 The Authors.

Published by Elsevier Inc.

This is an open access article under the CC BY-NC-ND license

(<http://creativecommons.org/licenses/by-nc-nd/4.0/>).

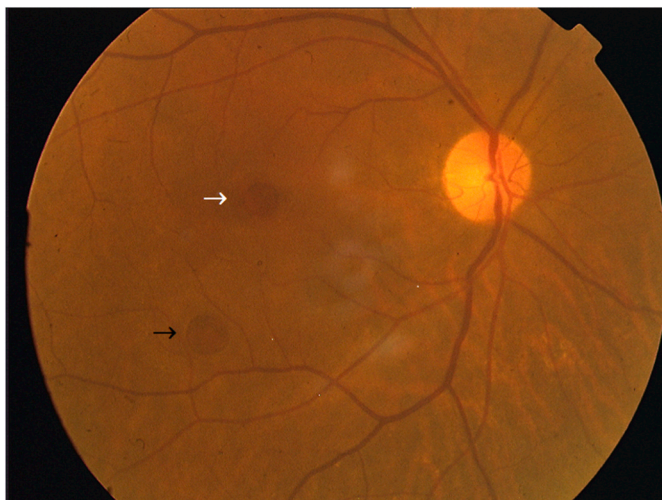


Fig. 1. Color fundus photography showing the central (white arrow) and paracentral (black arrow) full-thickness retinal holes in the right eye before surgery. (For interpretation of the references to colour in this figure legend, the reader is referred to the Web version of this article.)

the center of the macular hole and the center of the posterior retinal hole was 2564 μm (Fig. 2A).

The minimum inner diameter was 677 μm and 778 μm in the FTMH and posterior retinal hole, respectively. A standard three-port sutureless 25-gauge pars plana vitrectomy (Constellation, Alcon Laboratories) was performed under local anesthesia. After core vitrectomy ILM was stained using 0.1 mL of Membraneblue-dual (DORC, Zuidland, The Netherlands). The inverted ILM flap technique as originally described by Michalewska et al. was performed.³ The ILM was grasped and peeled off in a circular fashion around the two FTRHs. A fragment of the peeled-off ILM anchored on the holes edges was left and inverted/inserted into the gaps using the ILM microforceps.

At the end of the surgery a fluid-air exchange was performed, followed by injection of 20% sulfur hexafluoride (SF6) long-acting gas. The patient was instructed to keep a face-down position for 5 days.

One day after surgery, IOP was 19 mmHg and residual SF6 gas bubble 70%. A complete closure of both FTRHs was achieved at 1-month and persisted at 3-months, where SD-OCT displayed an incomplete outer retina layers restoration (Fig. 2B).

BCVA improved to 20/80 at month 1 and 20/63 at month 3 and no intraoperative or postoperative complications were recorded.

3. Discussion

Most idiopathic FTMHs start as a central retinal dehiscence that

gradually increase in size by centrifugal retraction. The presence of a paracentral associated FTRH is a very rare finding, particularly in patients who have never undergone vitreoretinal surgery. Cheng et al. described a double MH, spontaneously coalescing into a single large hole after a period of 10 weeks.⁴ This report further influenced our decision to perform the surgery considering the risk of a possible coalescence of the two retinal holes in a single very large FTMH. Later in 2005, Peiretti et al. described a case of “apparent” double MH where the illusion of a double MH was due to the presence of a FTMH superiorly and a second apparent lamellar hole inferiorly separated by a bridge of foveal tissue.⁵ Nevertheless, in our case the two FTRHs were separated from each other by a bridge of retinal tissue.

It is difficult to determine whether the posterior FTRH occurred before, after or at the same time with the macular one. The retinal holes formation might be initiated by the anterior-posterior traction at two different sites of strong focal vitreoretinal adhesion. Alternatively, it can be speculated that a tangential traction may have caused the formation of the paracentral FTRH following the macular one.

Finally, a combination of the tangential and anterior-posterior forces may have cooperated to create the two retinal openings at the same time.

Govetto et al. recently proposed the Müller cells as main determinants of force transmission in tractional macular disorders.⁶ In the foveal region Müller cells are straight and transmit mechanical forces to the outer retina favoring macular hole formation and other abnormalities of the central foveal bouquet.^{6,7} On the contrary, the parafoveal Müller cells with the characteristic z-shaped pattern may be protective against macular hole formation.⁶ The Henle fibre’s portion of parafoveal Müller cells have been measured by Drasdo et al. who reported a maximum length projected onto the external limiting membrane of 406–664 μm temporal to the fovea in radially oriented cross-sections of human retinas.⁸ Moreover the horizontal part of the z-shaped cells was maximum at 1.5 mm from the center of the fovea and shortened progressively up to 3 mm, where the cells are essentially vertical.⁸ This could further explain the onset of the posterior retinal hole at 2.56 mm from the fovea in a locus minoris resistentiae.

According to the recent literature, the inverted flap technique is more effective in achieving MH closure especially for larger ones (>400 μm).^{9,10}

Nevertheless, fibrotic or atrophic changes can cause incomplete outer retina layers restoration process,¹¹ as occurred in our case.

4. Conclusion

In summary, we present a case of non-iatrogenic macular and posterior FTRHs treated at the same time with an inverted ILM flap technique. This report shows that the surgical approach of an inverted ILM flap on each hole is a feasible and safe treatment option in this rare

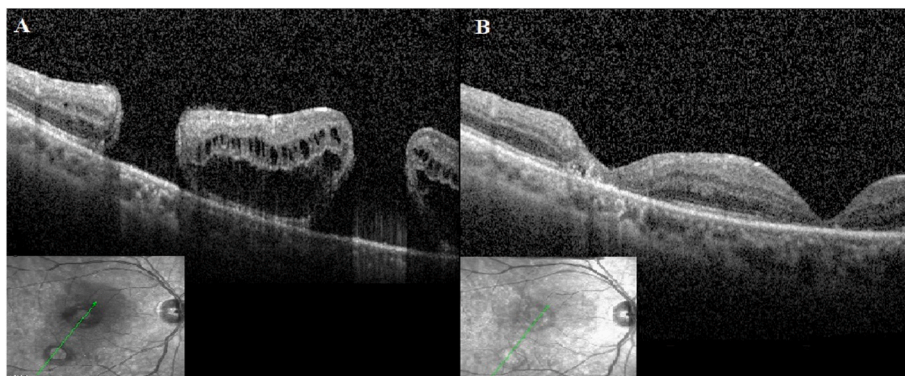


Fig. 2. (A) Baseline radial spectral-domain optical coherence tomography (SD-OCT) scan confirming the presence of two full-thickness macular holes with intraretinal cysts. (B) Tracked SD-OCT scan at month 3 showing closure of both retinal holes, reabsorption of intraretinal cysts and disruption of the outer retinal layers.

condition.

Patient consent

The patient consented to publication of the case in writing.

Funding statement

No funding or grant support.

Authorship

All authors attest that they meet the current ICMJE criteria for Authorship.

Declaration of competing interest

The authors declare that they have no known competing interests or personal relationships that could have appeared to influence the work reported in this paper.

Acknowledgements

None.

References

1. Gass JDM. Idiopathic senile macular hole: its early stages and pathogenesis. *Arch Ophthalmol*. 1988;106(5):629–639.
2. Sandali O, El Sanharawi M, Basli E, et al. Paracentral retinal holes occurring after macular surgery: incidence, clinical features, and evolution. *Graefes Arch Clin Exp Ophthalmol*. 2012;250(8):1137–1142.
3. Michalewska Z, Michalewski J, Adelman RA, Nawrocki J. Inverted internal limiting membrane flap technique for large macular holes. *Ophthalmology*. 2010;117(10):2018–2025.
4. Cheng ACK, Kwok AKH, Bhende P, Lam DSC. A case of double idiopathic macular holes. *Retina*. 2000;20(5):576–577.
5. Peiretti E, Fisher Y, Spaide RF, Goldberg D. Optical coherence tomography in a case of apparent double macular holes. *Retina*. 2005;25(8):1113–1115.
6. Govetto A, Hubschman JP, Sarraf D, et al. The role of Müller cells in tractional macular disorders: an optical coherence tomography study and physical model of mechanical force transmission. *Br J Ophthalmol*. 2020;104(4):466–472.
7. Govetto A, Bhavsar KV, Virgili G, et al. Tractional abnormalities of the central foveal bouquet in epiretinal membranes: clinical spectrum and pathophysiological perspectives. *Am J Ophthalmol*. 2017;184:167–180.
8. Drasdo N, Millican CL, Katholi CR, Curcio CA. The length of Henle fibers in the human retina and a model of ganglion receptive field density in the visual field. *Vis Res*. 2007;47(22):2901–2911.
9. Marques RE, Sousa DC, Leal I, Faria MY, Marques-Neves C. Complete ILM peeling versus inverted flap technique for macular hole surgery: a meta-analysis. *Ophthalmic Surg Lasers Imaging Retina*. 2020;51(3):187–A2.
10. Rizzo S, Tartaro R, Barca F, Caporossi T, Bacherini D, Giansanti F. Internal limiting membrane peeling versus inverted flap technique for treatment of full-thickness macular holes: a comparative study in a large series of patients. *Retina*. 2018;38:S73–S78.
11. Iovino C, Caminiti G, Miccoli M, Nasini F, Casini G, Peiretti E. Comparison of inverted flap and subretinal aspiration technique in full-thickness macular hole surgery: a randomized controlled study. *Eur J Ophthalmol*. 2018;28:324–328. <https://doi.org/10.5301/ejo.5001040>.