

# Image-based Bone Density Classification Using Fractal Dimensions and Histological Analysis of Implant Recipient Site

Elie Hayek<sup>1</sup>, Georges Aoun<sup>1</sup>,  
Hassem Geha<sup>2</sup>, Ibrahim  
Nasseh<sup>1</sup>

<sup>1</sup>Department of Oral Medicine and  
Maxillofacial Radiology, Faculty of Dental  
Medicine, Lebanese University, Beirut,  
Lebanon

<sup>2</sup>Department of Comprehensive Dentistry,  
University of Texas Health Science Center  
San Antonio, San Antonio, Texas, USA

Corresponding author: Professor Georges  
Aoun, Head of Department of Oral Medicine  
and Maxillofacial Radiology, Faculty of  
Dental Medicine, Lebanese University, Beirut,  
Lebanon. E-mail: dr.georgesoun@gmail.com.  
ORCID ID: <http://orcid.org/0000-0001-5073-6882>.

doi: 10.5455/aim.2020.28.272-277

ACTA INFORM MED. 2020 DEC 28(4): 272-277

Received: Nov 05, 2020

Accepted: Dec 11, 2020

© 2020 Elie Hayek, Georges Aoun, Hassem Geha,  
Ibrahim Nasseh

This is an Open Access article distributed under the  
terms of the Creative Commons Attribution Non-  
Commercial License (<http://creativecommons.org/licenses/by-nc/4.0/>) which permits unrestricted non-  
commercial use, distribution, and reproduction in any  
medium, provided the original work is properly cited.

## ABSTRACT

**Background:** Success of dental implants is affected by the quality and density of the alveolar bone. These parameters are essential for implant stability and influence its load-bearing capacity. Their assessment is usually based on preoperative radiographs used as a tool prior to implant procedures. **Objective:** The aim of the study was to compare the bone density of surgically harvested bone specimens at implant recipient sites in the maxillary and mandibular posterior region using histological analysis to the radiographic bone density using fractal dimension for reliability and determining an image based classification of bone density prior surgery. **Methods:** Fifty implants were placed in the posterior region of male patients, (twenty five implants in the maxilla and twenty five in the mandible). The edentulous regions were presurgically assessed using Photo Stimulable Phosphor Plate (PSP) intra-oral radiographs and the fractal dimension box counting of region of interest was calculated at the implant recipient site. During surgery, bone core specimens were trephined, and bone densities and minerals parameters were evaluated based on histological analysis using SEM (Scanning Electron Microscopy), and atomic absorption spectrometry. **Results:** Fractal dimensions (FD) values for the same region of interest (ROI) selected on the radiographs of bone blocks and edentulous sites were different but showed a proportional variation in molar and premolar region of the maxilla and mandible. Bone density results, calculated by the ratio of bone mass (BM) to the bone volume (BV) of the bone core specimen ( $D=M/V$ ), increased in the mandibular bone blocks, and decreased in the maxilla specimens. Moreover, fractal dimension values of preoperative radiographs at implant recipient sites and bone density of trephined showed a statistically similar distribution. However, no significant difference was shown in the percentage of minerals contents and mass of calcium phosphate of each bone specimen between maxilla and mandible based on scanning electron microscopy analysis. Four types of bone densities were classified according to the distribution of FD values based on preoperative radiographs and on the densities of bone cores calculations. **Conclusion:** Radiographic estimation of bone quality calculated with fractal dimension could be a useful, non-invasive tool when using preoperative intra-oral radiographs to predict bone density at implant recipient sites with caution and limits concerning the kind of digital radiographs and size of region of interest, especially when these results were based with bone specimens harvested from implant site as an absolute reference.

**Keywords:** Fractal dimension; bone density; bone specimen; periapical radiograph.

## 1. INTRODUCTION

The success rate of dental implant is considered to be influenced by the quantity of bone surrounding the implant and the quality of bone which is one of the most critical parameters for the success of implant placement (1, 2). Comparing the two jaws, the success rate of implants in the lower jaw is higher than the

upper based on the literature data (3-5), moreover a survey of studies on implant planning and treatment, showed a diversity of classification systems and measurement units of bone quality (6).

Generally, the quality of bone is considered as the sum of all the characteristics of bone that influence its resistance to fracture (7), including

the structural aspects and the degree of bone tissue mineralization (8-11).

The density is the quality of radiopacity, the concept of Mass per Volume ( $D=M/V$ ) is based that the absorption of x-ray is proportional to the mass of calcium in that unit of bone volume. The bone density is a key factor in determining the treatment planning, surgical approach and healing time in an edentulous site (12).

However, many clinicians in order to differentiate the different type of bone use bone density as an objective indicator to be evaluated at implant sites based on preoperative radiographs (13-15).

In the field of dentistry, several classification of bone density has been proposed for assessing bone quality. Lekholm and Zarb (16), classified alveolar bone quality from type 1 to type 4 according to the radiographic morphology and amount of cortical bone versus trabecular bone. Mish et al. (17), adjusted this classification based on a subjective tactile sensations and assessment detected by the surgeon during implant drilling, yet these classifications are still without the analysis of bone tissue specimens as a reference and for additional observation.

Fractal analysis (FA) is a method which a complex and irregular body structures may be evaluated mathematically, and the fractal dimension (FD) is the definition of the quantitative outcome of this method (18). Many studies have been using the fractal analysis method to explore bone structures (19-22).

In dentistry, FA has been applied to analyze the images of panoramic and periapical radiographs which are the most frequently used (23), and to assess and quantify the trabecular bone pattern of the jaw through counting the bone marrow and trabecular bone interface (24).

This method has been employed by many researchers for bone mineral density (BMD) investigation. When the box counting value is high, the trabecular and medullar bone boundary is more complex. Moreover, the reduction of bone density values corresponds to a diminishing of fractal dimension (25). Fractal analysis may be calculated from digitalized images using a computer program described by White & Rudolph where the morphology features of the trabecular bone can be measured (26). Box counting algorithm method was used for calculation which considered easy and accessible (27, 28), and frequently used by radiologist to predict bone density (29) and to facilitate quantitative evaluation of the bone microarchitecture from the high precision of digital images available (21).

Very few studies have estimated bone density by analyzing minerals content and ratio mass to volume calculation of bone biopsies in order to provide supplementary information.

## 2. AIM

The aim of this study is to compare the fractal dimension values of two similar regions of interest, one from a preoperative implant site, and the other from a trephined bone block. Another aim is to propose a suitable image-based classification of bone density type by correlating between the bone density values calculated

from bone biopsies, the mass of calcium phosphate, and the fractal dimension values from preoperative radiographs to assess the bone quality before implant placement.

## 3. MATERIAL AND METHODS

### Ethical aspects

This study was conducted in the Division of Maxillofacial Radiology and approved by the Institutional Ethical Board of the Lebanese University (no 52018/117). All patients were given detailed information about the study objectives and procedures, and their written informed consent was obtained.

### Inclusion criteria

The study included only healthy male patients ranging in age between 20 and 50, requiring at least one implantation in the premolar/molar region of the maxilla or mandible with more than 10 mm of a residual alveolar bone crest height and more than 5 mm of residual bone crest width based on cone beam computed tomography (CBCT) images.

### Exclusion criteria

The following patients were excluded from the study: (1) patients with systemic conditions, (2) patients under medications affecting the bone metabolism, (3) patients with alveolar bone lesions, (4) patients having received any type of bone graft, (5) smokers.

### Surgical procedures

All individuals were subjected to full mouth prophylaxis sessions prior to intraoral radiographs and surgeries. We placed 50 implants equally in premolar and molar areas of the maxilla and the mandible. All implants were 10 mm long with a 4 mm diameter.

Implant surgeries were performed by one experienced surgeon with a standardized protocol. Cylindrical bone specimens were harvested during the surgery using a trephine bur (Trepan Bur, 2.0 mm diameter, 7 mm long, Komet Dental. Gebr. Brasseler GmbH & Co, Germany), and dental implant fixtures were then inserted into the edentulous site.

### Digital periapical image acquisition

Size 2 Photostimulable phosphor (PSP) plate from the VistaScan digital radiographic system (Dürr Dental) were used and scanned at 1270 dpi (25 lp/mm) special resolution. The Kodak dental X-ray unit was adjusted to operate at 70 kVp, 7 mA, an exposure time of 0.16 second, and a focus-receptor distance of 30 cm. Two radiographs were obtained, one for the maxillary or mandibular molar/premolar region, and a second for the harvested bone block using paralleling technique and posterior paralleling device with standard exposure. Images were stored on a personal computer and given to the investigator for fractal dimension (FD) calculations.

### Region of interest selection

Two identical rectangular regions of interest (ROI) were marked on the radiographic images measuring 25x50 pixels, the first ROI was drawn at the edentulous implant site on the preoperative radiograph, and the second was placed within the bone specimen radiograph (Figure 1). All ROIs obtained were saved in the computer memory.

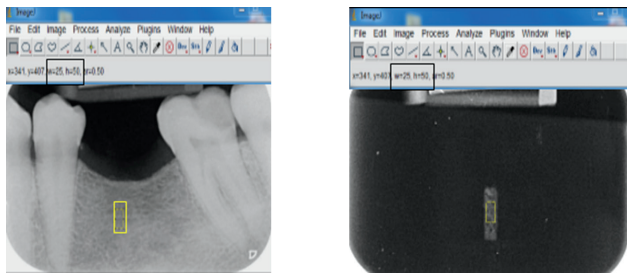


Figure 1. ImageJ program was used to select two identical ROI of 25x50 pixels on two radiographs, one for preoperative edentulous site and second for bone core specimen.




Figure 2. The image processing steps includes cropping of the regions of interest (ROI), duplication of the ROI and use a blurred Gaussian filter, in brightness the subtraction of ROI from the original image, binarization, and skeletonization.

#### Assessment of fractal dimension

ImageJ software (version 1.36b, U.S. National Institutes of Health) was used to analyze the ROIs. The sequence includes cropping of the regions of interest (ROI), duplication of the ROI and the use a blurred Gaussian filter to remove large-scale variations, in brightness the subtraction of ROI from the original image, binarization, and skeletonization (Figure 2).

**Bone core specimen analysis** The analytical information of bone biopsy was done using Scanning Electron Microscopy (SEM) (Seron technologies Brand). Before SEM treatment, the mass of each bone specimen was measured using a scientific electronic balance. The sample was placed on a holder using Carbone tape, a thin film of gold was deposit on the sample to make its surface conductive (deposition time was 20-30 sec), the bone specimen was then placed in a chamber of high vacuum and finally an electron beam initiate to hit the sample surface in order to obtain a various signals. Two signals were used: the secondary electrons that display an image of the sample's surface and characteristic x-ray that allows elemental quantification of elements present in the sample. Each of these two signals has their own detector embedded in the Energy Dispersive X-ray machine (EDX).

This technique was performed by a blinded examiner using a standard protocol to measure the percentage of mineral contents founded in the bone biopsy. For the descriptive histological analysis, the parameters evaluated were: percentage of calcium, phosphorus inside bone specimen, mass of the specimen then the density of bone biopsy was calculated from the ratio of mass and volume of the specimen ( $D=M/V$ ).

The mass of calcium phosphate was calculated as follows: 10 ml of HCL was added to the specimen and the mixture was heated for 5 hours on a hot plate at a 60°C of

temperature, and then was diluted up to 100 ml to have a liquid solution. After that the solution was filtered by a 45µm syringe filter and was ready for the analysis by atomic absorption spectrometry to measure the concentration of calcium phosphate in mg/l, and then the mass of calcium phosphate in the bone specimen was calculated.

#### Statistical Analysis

All results were saved in an Excel sheet and data were statistically analyzed using the IBM® SPSS® software version 20.0 (SPSS Inc, Chicago, Illinois). Box counting values based on radiographs and bone specimen densities and minerals contents were compared. The correlations of bone specimen densities based on histological analysis with fractal dimensions values based on radiographs were examined using uni- and/or multivariate regression analyses. Results were considered statistically significant if  $p < 0.05$ .

## 4. RESULTS

The results showed that the data distribution was normal.

Of the 50 implants placed, 25 implants were inserted in the posterior region of the maxilla and 25 implants in the posterior region of the mandible. In the maxilla, seven implants were installed in molar sites (three in the left side and four in the right), and 18 implants in premolar sites (12 in the left side and six in the right). In the mandible, among the 25 implants placed, 17 were in molar sites (11 in the right side and six in the left) and eight in premolar sites (two implants in the left side and six in the right). The distribution of implants insertions is listed in Table 1.

	Molar		Premolar		Total	
	Right	Left	Right	Left	Right	Left
Maxilla	4	3	6	12	10	15
Mandible	11	6	6	2	17	8
	15	9	12	14	27	23
Total	24		26		50	

Table 1. Distribution of implants' placement in the maxilla and mandible posterior region

Fractal dimension of implant sites calculated using preoperative radiographs showed an increased in the average of values from molar to premolar maxillary and from molar to premolar mandibular and between maxilla and mandible separately (Table 2).

When using the bone block radiographs, the average of FD values were lower than the values at implant sites despite the same ROI's were used. In other words, all results showed a proportional distribution to these obtained from preoperative radiographs in regards to maxillary and mandibular molar and premolar regions or between the two arches but with lower values (Table 3).

Significant increases in bone mass, therefore increases in bone density were noted in mandibular bone core specimens compared to those in maxillary specimens. However, using multivariate regression analysis, no correlation was noted between the amount and percentage of minerals component (calcium, phosphorus) and bone

Region of Interest 25 x 50 pixels	Preoperative FD at implant recipient site								
	Molar			Premolar			Posterior Region		
	Min	Max	Av.	Min	Max	Av.	Min	Max	Av.
Maxilla	1.398	1.486	1.451	1.479	1.598	1.544	1.398	1.598	1.52
Mandible	1.522	1.588	1.550	1.506	1.644	1.563	1.506	1.611	1.553

Table 2. Distribution and comparison of implant site fractal dimension values determined by the radiographs.

Region of Interest 25 x 50 pixels	FD of bone core specimen								
	Molar			Premolar			Posterior Region		
	Min	Max	Av.	Min	Max	Av.	Min	Max	Av.
Maxilla	1.387	1.475	1.434	1.316	1.578	1.485	1.316	1.578	1.472
Mandible	1.405	1.553	1.498	1.4	1.56	1.502	1.4	1.56	1.499

Table 3. Distribution and comparison of bone core specimen fractal dimension values determined by the radiographs.

Bone core specimen	Calcium %	Phosphorus %	Mass of Calcium Phosphate	Density of Bone D=M/V
Maxillary Molar	21.326	11.685	1.849	0.150
Maxillary Premolar	23.442	12.173	2.175	0.305
Maxillary Posterior Region	22.384	11.929	2.012	0.227
Mandibular Molar	21.833	10.889	2.735	0.379
Mandibular Premolar	26.236	13.873	3.003	0.489
Mandibular Posterior Region	22.982	11.784	2.869	0.408

Table 4. Histological analysis of bone minerals and bone core specimens' densities calculations obtained from recipient implant sites

	FD of Pre-Operative Radiograph	FD of bone core specimen	Density of Bone Specimen (g/cm <sup>3</sup> )	Mass of Calcium Phosphate (mg)	Type of Bone Density
Maxillary Molar	1.451	1.434	0.150	1.849	Type 4 (FD<1.50)
Maxillary Premolar	1.544	1.485	0.305	2.175	Type 3 (1.55<FD>1.50)
Maxillary Posterior Region	1.520	1.472	0.227	2.012	Type 3- Type 4 1.55<FD>1.45
Mandibular Molar	1.550	1.498	0.379	2.735	Type 3 (1.55<FD>1.50)
Mandibular Premolar	1.563	1.502	0.489	3.003	Type 2 (1.60<FD>1.55)
Mandibular Posterior Region	1.553	1.499	0.408	2.869	Type 2- Type 3 1.60FD1.50

Table 5. Correlations of histological characteristics of bone specimen density with the fractal dimensions assessed by radiographs and types of bone densities

densities and there was no significant variability of these results in mandibular and maxillary specimens separately, only mass of calcium phosphate values increased with bone densities (Table 4).

Significant increases in bone densities calculation were observed in the posterior region of the mandible compared to those calculated in the maxilla, and increase in premolar regions of each jaw compared to molar regions (Table 5).

However, comparing image based bone type assessed by FD values using preoperative radiographs in the posterior regions of maxilla and mandible and densities of

bone block respectively; a positive significant correlation was noted. As well, when the maxilla and mandible were separately examined, the correlation could still be found. A classification was proposed by the authors according to the distribution of FD values and bone densities, divided bone densities into 4 types. Type 1: FD1.60, Type 2: 1.60FD1.55, Type 3: 1.55FD1.50, Type 4: FD1.50. In our study, classification Type 2-Type 3 were noted in the posterior regions of the mandible with FD values between 1,550 and 1,563, whereas type 3-type 4 were found in the maxilla with FD values between 1.451 to 1.544 (Table 5).

## 5. DISCUSSION

Quality of bone is one of the keys of success in the implant treatment plan but it is also unfortunately, one of the variants that cannot be accurately determined prior to implant placement. Implant stability is due to the amount of cortical bone whereas the long-term stability is the responsibility of cancellous bone. Bone architecture and constituents of cancellous bone have a considerable interest in evaluating quality of bone.

Assessment of bone quality and bone density based on preoperative radiographs has frequently been used as a tool prior to implant procedures.

This study was undertaken to assess the bone density at 50 implant sites distributed equally in the posterior regions of maxilla and mandible, using fractal dimension with periapical digital radiograph, and 50 bone cores, where the implants would engage, obtained from the central part of the implant sites excluding the buccal and lingual cortical plates and then radiographed. The

bone blocks were examined to calculate bone densities by calculating mass and volume and calcium phosphate mass. It has been reported that thicknesses variations of the buccal and lingual cortical plates at different sites may affect the radiographic diagnosis but not when the specimens bone cores were considered as a reference (30).

Fractal analysis provide the clinician with box counting values, a subjective method of evaluating bone density for a proposed implant site using preoperative intra-oral radiograph.

Geraets and van der Stelt (31) stated that all stages in the “analytic chain” of FA have an influence in the assessment of bone due to the wide variations of analyzing methods.

In the present study a specific methodology has been followed using the ImageJ software to ensure that the ROIs were exactly similar on the radiographic images.

Previous studies stated that FA of PSP radiographic images of alveolar bone is influenced by some digital enhancement filters and the spatial resolution of the system (32). Therefore, the same image specifications and processing conditions should be used for FD comparison.

Our results showed that the bone density assessments by FD as a primary tool using preoperative radiographs present higher values in the mandible than the maxilla and differences between molar/premolar regions in both arches. Reported results on human cadaver jaw bone specimens using micro-CT (33-34) are consistent with our results.

FD of bone cores in table 3 showed a similar and proportional distribution of the FD but with lower values compared to the FD values in table 2 for the same ROI's. This is attributed to the presence of the buccal and lingual cortical plates of the preoperative radiographs.

A very few studies investigated the local elemental composition of bone core specimen using SEM, which allows, for example, the percentage of calcium and phosphorus and mass of calcium phosphate to be measured.

In this current study, the measures of quantitative components of bone cores were significant. The ratio of mass to volume and therefore bone densities increases in mandibles more than in maxilla that the mass and volume of specimens harvested from mandibles was larger than of those obtained from maxilla, and that denser bones were harvested from the mandibular implant sites than from maxillary implant sites. The mean value of bone density in the posterior region of maxilla was 0.227 comparing to 0.408 in the mandible. Conversely, no significant differences were observed when measuring the mineral composition of bone between maxilla (22.384 of calcium, 11.929 of phosphorus) and mandible (22.929 of calcium, 11.784 of phosphorus). However, the reason that the mass of calcium phosphate matched with bone density value is still unclear.

In our study, we proposed a bone density classification according to the distribution of FD values based on preoperative radiographs and on the densities of bone cores calculations and we divided bone densities into four

types:

Type 1:  $FD \geq 1.60$ , Type 2:  $1.60 > FD \geq 1.55$ , Type 3:  $1.55 > FD \geq 1.50$ , Type 4:  $FD < 1.50$ .

A correlation was found between the bone density based analytical characteristics of bone specimens and fractal dimension values based on intra oral radiographs of the posterior region in either maxilla or mandible. Moreover, the types of bone density in molar or premolar region assessed based on fractal dimension values of each region and bone densities respectively, were analyzed and classified per region as follow:

Maxillary molar region: Type 4 with FD mean values 1.451 and bone densities average 0.150 g/cm<sup>3</sup>

Maxillary premolar region: Type 3 with FD mean values is 1.544 and bone densities 0.305 g/cm<sup>3</sup>

Mandibular molar region: Type 3 with FD mean values is 1.550 and bone densities 0.379 g/cm<sup>3</sup>

Mandibular premolar region: Type 2 average of FD values is 1.563 and bone densities 0.489 g/cm<sup>3</sup>

In summary, Type 2-Type 3 of bone were noted in the posterior regions of the mandible with FD values between 1.550 and 1.563 and bone densities average 0.408 g/cm<sup>3</sup>, while Type 3-Type 4 were found in the maxilla with FD values between 1.451 to 1.544 and bone densities average 0.227 g/cm<sup>3</sup>.

The suggested value for the FD of a normal or healthy trabecular bone of the jaws is approximately 1.5 in periapical images (35). In our study, similar results were reported, while in some other studies with same groups, a higher (1.74) or lower (1.05) FD values were detected (18-36). Variation in image parameters or different size of ROI can justify such differences in values.

When comparing fractal dimensions and bone densities based respectively on intra-oral radiographs and bone core specimens, a significant correlation was noted but this was not limited to mandible or maxilla but also to the molar and premolar region when Type 2 and Type 3 and Type 4 were compared.

According to the above results, assessment of bone density based on periapical radiographs using fractal dimension values might be useful, particularly when these values were compared to bone core densities harvested from the recipient implant sites as an absolute reference.

Therefore, image-based classification using fractal dimension to predict the bone type prior to implant treatment may be clinically time-consuming and a determining factor in implant design, surgical approach, and healing time.

## 6. CONCLUSION

Our study demonstrates a correlation between fractal dimension values and bone core specimens densities harvested from the recipient implant sites and proposed an image-based classification of bone density in the posterior regions of maxilla and mandible and separately in molar and premolar region of each jaw.

Fractal dimension provides an economical and easy option to measure the density at implant sites, as opposed to the expensive and unfeasible density assessment of other techniques.

Image-based bone density for the anterior region in maxilla and mandibles must be established in further studies.

- **Authors' contribution:** All authors were included in all steps of the article preparation. Final proof reading was made by the first and the corresponding authors.
- **Conflict of interest:** None declared.
- **Financial support and sponsorship:** Nil.

## REFERENCES

1. Morris HE, Ochi S, Crum P, Orenstein I, Plezia R. Bone density: its influence on implant stability after uncovering. *J Oral Implantol.* 2003; 29(6): 263-269.
2. Lioubavina-Hack N, Lang NP, Karring T. Significance of primary stability for osseointegration of dental implants. *Clin Oral Implants Res.* 2006; 17(3): 244-250.
3. Comfort MB, Chu FCS, Chai J, Wat PYP, Chow TW. A 5-year prospective study on small diameter screw-shaped oral implants. *J Oral Rehabil.* 2005; 32(5): 341-345.
4. Turkyilmaz I. Clinical and radiological results of patients treated with two loading protocols for mandibular overdentures on Brånemark implants. *J Clin Periodontol.* 2006; 33(3): 233-238.
5. Turkyilmaz I, Tözüm TF, Tumer C. Bone density assessments of oral implant sites using computerized tomography. *J Oral Rehabil.* 2007; 34(4): 267-272.
6. Ribeiro-Rotta RF, Lindh C, Pereira AC, Rohlin M. Ambiguity in bone tissue characteristics as presented in studies on dental implant planning and placement: A systematic review. *Clin Oral Implants Res.* 2011; 22(8): 789-801.
7. Fyhrrie DP. Summary — Measuring “bone quality”. *J Musculoskelet Neuronal Interact.* 2005; 5(4): 318-320.
8. Bergkvist G, Koh KJ, Sahlholm S, Klintström E, Lindh C. Bone density at implant sites and its relationship to assessment of bone quality and treatment outcome. *Int J Oral Maxillofac Implants.* 2010; 25(2): 321-328.
9. Molly L. Bone density and primary stability in implant therapy. *Clin Oral Implants Res.* 2006; 17: 124-135.
10. Marquezan M, Osório A, Sant'Anna E, Souza MM, Maia L. Does bone mineral density influence the primary stability of dental implants? A systematic review. *Clin Oral Implants Res.* 2012; 23(7): 767-774.
11. Buck DL, Wheeler PW. A density comparison of human alveolar and retromolar bone. *Angle Orthod.* 1969; 39(2): 133-136.
12. Suvarna PV, Jaju PP, Subramaniam AV, Jain S. Density evaluation of pre-implant sites by dentascan software. *J Int Clin Dent Res Organ.* 2010; 2(1): 4-10.
13. Wakimoto M, Matsumura T, Ueno T, Mizukawa N, Yanagi Y, Iida S. Bone quality and quantity of the anterior maxillary trabecular bone in dental implant sites. *Clin Oral Implants Res.* 2012; 23(11): 1314-1319.
14. Norton MR, Gamble C. Bone classification: an objective scale of bone density using the computerized tomography scan. *Clin Oral Implants Res.* 2001; 12(1): 79-84.
15. Choi JH, Park CH, Yi SW, Lim HJ, Hwang HS. Bone density measurement in interdental areas with simulated placement of orthodontic miniscrew implants. *Am J Orthod Dentofacial Orthop.* 2009; 136(6): 766.
16. Lekholm U, Zarb GA. Patient selection and preparation. In: Brånemark P-I, Zarb GA, Albrektsson T, eds. *Tissue-Integrated Prostheses: Osseointegration in Clinical Dentistry.* Chicago: Quintessence; 1985:199-209.
17. Misch CE. Density of bone: effect on treatment plans, surgical approach, healing, and progressive boen loading. *Int J Oral Implantol.* 1990; 6(2): 23-31.
18. Sener E, Cinarcik S, Baksi BG. Use of fractal analysis for the discrimination of trabecular changes between individuals with healthy gingiva or moderate periodontitis. *J Periodontol.* 2015; 86(12): 1364-1369.
19. Baksi BG, Fidler A. Fractal analysis of periapical bone from lossy compressed radiographs: a comparison of two lossy compression methods. *J Digit Imaging.* 2011; 24(6): 993-998.
20. Zeytinoğlu M, İlhan B, Dündar N, Boyacıoğlu H. Fractal analysis for the assessment of trabecular peri-implant alveolar bone using panoramic radiographs. *Clin Oral Investig.* 2015; 19(2): 519-524.
21. Kavitha MS, An S-Y, An C-H, Huh K-H, Yi W-J, Heo M-S, et al. Texture analysis of mandibular cortical bone on digital dental panoramic radiographs for the diagnosis of osteoporosis in Korean women. *Oral Surg Oral Med Oral Pathol Oral Radiol.* 2015; 119(3): 346-356.
22. Hwang JJ, Lee J-H, Han S-S, Kim YH, Jeong H-G, Choi YJ, et al. Strut analysis for osteoporosis detection model using dental panoramic radiography. *Dentomaxillofac Radiol.* 2017; 46(7): 20170006
23. Kato CN, Barra SG, Tavares NPK, Amaral TMP, Brasileiro CB, Mesquita RA, et al. Use of fractal analysis in dental images: a systematic review. *Dentomaxillofac Radiol.* 2020; 49(2): 20180457.
24. Koca H, Ergün S, Güneri P, Boyacıoğlu H. Evaluation of trabecular bone healing by fractal analysis and digital subtraction radiography on digitized panoramic radiographs: a preliminary study. *Oral Radiol.* 2010; 26: 1-8.
25. Southard TE, Southard KA, Jakobsen JR, Hillis SL, Najim CA. Fractal dimension in radiographic analysis of alveolar process bone. *Oral Surg Oral Med Oral Pathol Oral Radiol Endod.* 1996; 82(5): 569-576.
26. White SC, Rudolph DJ. Alterations of the trabecular pattern of the jaws in patients with osteoporosis. *Oral Surg Oral Med Oral Pathol Oral Radiol Endod.* 1999; 88(5): 628-635.
27. Leite AF, de Souza Figueiredo PT, Caracas H, Sindeaux R, Guimarães ATB, Lazarte L, et al. Systematic review with hierarchical clustering analysis for the fractal dimension in assessment of skeletal bone mineral density using dental radiographs. *Oral Radiol.* 2015; 31(1): 1-13.
28. Arsan B, Köse TE, Çene E, Özcan İ. Assessment of the trabecular structure of mandibular condyles in patients with temporomandibular disorders using fractal analysis. *Oral Surg Oral Med Oral Pathol Oral Radiol.* 2017; 123(3): 382-391.
29. Suer BT, Yaman Z, Buyuksarac B. Correlation of fractal dimension values with implant insertion torque and resonance frequency values at implant recipient sites. *Int J Oral Maxillofac Implants.* 2016; 31(1): 55-62.
30. Flanagan D. A comparison of facial and lingual cortical thicknesses in edentulous maxillary and mandibular sites measured on computerized tomograms. *J Oral Implantol.* 2008; 34(5): 256-258.
31. Geraets WG, van der Stelt PF. Fractal properties of bone. *Dentomaxillofac Radiol.* 2000; 29(3): 144-153.
32. Oliveira-Santos N, Michels M, Freitas DQ, Haiter-Neto F, Oliveira ML. Influence of phosphor plate-based radiographic image specifications on fractal analysis of alveolar bone. *Oral Surg Oral Med Oral Pathol Oral Radiol.* 2019; 128(4): 418-423.
33. Katranji A, Misch K, Wang HL. Cortical bone thickness in dentate and edentulous human cadavers. *J Periodontol.* 2007; 78(5): 874-878.
34. Kim YJ, Henkin J. Micro-computed tomography assessment of human alveolar bone: bone density and three-dimensional micro-architecture. *Clin Implant Dent Relat Res.* 2015; 17(2): 307-313.
35. Amer ME, Heo M-S, Brooks SL, Benavides E. Anatomical variations of trabecular bone structure in intraoral radiographs using fractal and particles count analyses. *Imaging Sci Dent.* 2012; 42(1): 5-12.
36. Updike SX, Nowzari H. Fractal analysis of dental radiographs to detect periodontitis-induced trabecular changes. *J Periodontol Res.* 2008; 43(6): 658-664.