

Charles Diaper

Department Ophthalmology, South Glasgow University Hospitals, Glasgow, UK

Correspondence to: Mr Francis Carbonaro, Twin Research Unit, King's College, London, UK; francis.carbonaro@btopenworld.com

Informed consent was obtained for publication of figure 1.

doi: 10.1136/bjo.2007.117317

Accepted 27 February 2007

Competing interests: None declared.

References

- 1 **Biggs SL**, Font RL. Oncocytic lesions of the caruncle and other ocular adnexa. *Arch Ophthalmol* 1977;**95**:474–8.
- 2 **Hartman LJC**, Mourits MP, Canninga-van Dijk MR. An unusual tumour of the lacrimal gland. *Br J Ophthalmol* 2003;**87**:363.
- 3 **Cameron JR**, Barras CW. Oncocytoma of the eyelid. *Acta Ophthalmol Scand* 2005;**83**:125.
- 4 **deBree R**, Scheeren RA, Kummer A, *et al.* Nasolacrimal duct obstruction caused by an oncocytoma. *Rhinology* 2002;**40**:165–7.
- 5 **Shields CL**, Shields JA. Tumours of the conjunctiva and cornea. *Surv Ophthalmol* 2004;**49**:3–24.
- 6 **Luthra CL**, Doxanas MT, Green WR. Lesions of the caruncle: a clinicopathological study. *Surv Ophthalmol* 1978;**23**:183–95.
- 7 **Chang WJ**, Nowinski TS, Eagle RC, Jr. A large oncocytoma of the caruncle. *Arch Ophthalmol* 1995;**113**:382.
- 8 **Morgan MB**, Truitt CA, Romer C, *et al.* Ocular adnexal oncocytoma: a case series and clinicopathological review of the literature. *Am J Dermatopathol* 1998;**20**:487–90.
- 9 **Kaesr PF**, Uffer S, Zografos L, *et al.* Tumours of the caruncle: a clinicopathological correlation. *Am J Ophthalmol* 2006;**142**:448–55.
- 10 **Rennie IG**. Oncocytomas (oxyphil adenomas) of the lacrimal caruncle. *Br J Ophthalmol* 1980;**64**:935–9.

Centripetal retinal capillary proliferation in idiopathic parafoveal telangiectasis

We report two cases with idiopathic parafoveal telangiectasis (IPT) that showed a deep invasion of perifoveal capillaries within the substance of the fovea, obliterating the foveal avascular zone. All four eyes revealed characteristic findings of IPT, but demonstrated a deep layer of telangiectatic capillaries occupying the expected region of the foveal avascular zone, with retention of relatively good visual acuity. These cases indicate that the control of capillary growth in patients with IPT is defective, but the presence of vessels alone does not cause a marked decrease in visual acuity.

IPT is an acquired retinal disorder consisting of bilateral deep proliferation of telangiectatic perifoveal capillaries through the depth of the parafoveal macula, and also centripetally to an extent—in that patients with IPT have smaller foveal avascular zones (FAZs) than normal patients.¹ We report two patients with IPT who showed a deep invasion of perifoveal capillaries within the central fovea, causing an obliteration of the FAZ.

Case report

Case 1: A 49-year-old female had experienced gradual vision loss for several years bilaterally without treatment. Her visual acuity was 20/30 right eye and 20/100 left eye. Both eyes

revealed telangiectatic capillaries, intraretinal refractile deposits and right-angle venules in the macula (fig 1). Fluorescein angiography clearly demonstrated a deep layer of telangiectatic capillaries occupying the entire expected region of the FAZ. Optical coherence tomography (OCT) bilaterally demonstrated blunting of the foveal depression, hyper-reflectivity within the central fovea and of the outer nuclear layer in the macula consistent with the vascular infiltration, and disruption of the boundary between photoreceptor inner and outer segments.

Case 2: A 59-year-old female had a gradual vision loss to 20/50 right eye and 20/40 left eye. Both eyes revealed telangiectatic capillaries, intraretinal refractile deposits and right-angle venules (fig 2). A deep layer of telangiectatic capillaries invading into the expected region of the FAZ was highlighted by fluorescein angiography. OCT bilaterally showed hyper-reflectivity of the outer nuclear layers in the macula and a break of the hyper-reflective line between photoreceptor inner and outer segments. The right eye had a loss of the foveal depression and a small amount of subfoveal fluid, whereas the left eye had an intraretinal cavitation.

Comment

In addition to telangiectatic vessels, our patients had right-angle venules, greyish-white opacification of the macula, and inner retinal crystalline deposits, all of which are typical for IPT. Because of these findings, the likelihood of the vascular findings being congenital is unlikely. Congenital macrovessels² have been

reported with increased vascularity in the foveal region; however, macrovessels are usually solitary, unilateral, and are not associated with retinal opacification or inner retinal crystalline deposits. During embryological development, a superficial layer of capillaries forms in association with astrocytes around the future site of the foveal depression.³ These vessels are excluded from the central foveal region during development.⁴ Later, a deeper layer of capillaries forms, apparently secondary to vascular endothelial growth factor release by Muller cells.^{3,5} After the vessels form, the astrocytes retreat from around the fovea.⁴ For vessels to invade the central fovea later in life, some stimuli for their growth must be present. There are two principle cell types in the central fovea: photoreceptors and Muller cells. As Muller cells are responsible for directing the deeper layer of capillaries during embryology and our patients had a deep proliferation of capillaries into a region that is ordinarily occupied only by photoreceptors and Muller cells, there seems a possibility that the abnormal vessel growth was directed by Muller cells.

Abnormalities involving Muller cells have been implicated in macular structural abnormalities seen in IPT,⁶ including foveal cavitation, which occurred in one eye of the current cases. We⁶ suggested that such cavitation is probably attributed to the alteration at the site of a specialized Muller cell found in the inner portion of the fovea centralis—namely, the Muller cell cone.⁷ Recent reports have also demonstrated a gap at the level of the boundary of photoreceptor inner and outer

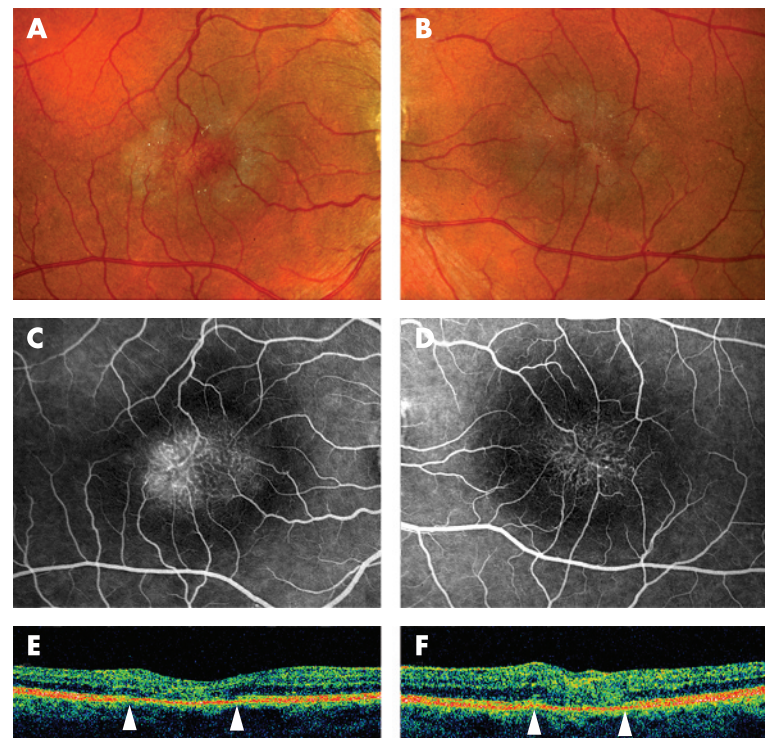


Figure 1 Case 1. A 49-year-old female with idiopathic parafoveal telangiectasis and obliteration of the foveal avascular zone. Color fundus photograph (A, right eye, B, left eye) demonstrated telangiectatic capillaries, intraretinal refractile deposits, right-angle venules and loss of macular transparency. Fluorescein angiography (C, right eye, D, left eye) revealed a deep layer of telangiectatic capillaries occupying the expected region of the foveal avascular zone. Optical coherence tomography (E, right eye, F, left eye), taken horizontally, demonstrated blunting of the foveal depression and hyper-reflectivity of the central fovea and of the outer nuclear layer in the macula. Disruption of the hyper-reflective line, considered as the boundary between photoreceptor inner and outer segments, was detected (E, F, between arrowheads).

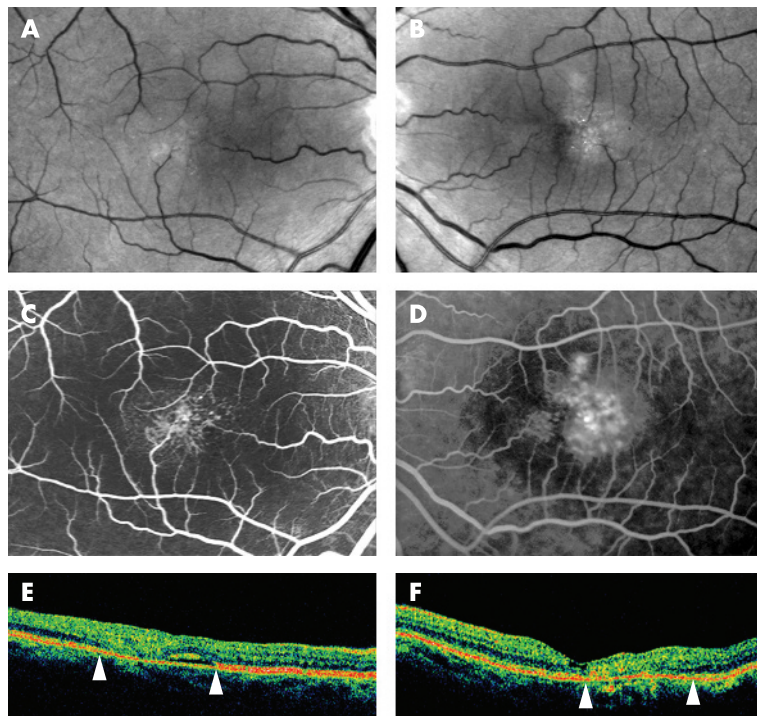


Figure 2 Case 2. A 59-year-old female with idiopathic parafoveal telangiectasis and obliteration of the foveal avascular zone. Red-free photograph (A, right eye, B, left eye) demonstrated telangiectatic capillaries, intraretinal refractile deposits, right-angle venules and loss of macular transparency. Fluorescein angiography (C, right eye, D, left eye) revealed a deep layer of telangiectatic capillaries invading into the expected region of the foveal avascular zone. Optical coherence tomography, taken horizontally, demonstrated hyper-reflectivity of the outer nuclear layer in the macula and a break of the boundary between photoreceptor inner and outer segments bilaterally (E, F, between arrowheads), a loss of the foveal depression and subretinal fluid in the central fovea of the right eye (E) and an inner foveal cavitation in the left eye (F).

segments as a characteristic OCT finding in IPT.^{8,9} Interestingly, experimental disruption of Muller cell metabolism induces photoreceptor dysmorphogenesis.¹⁰ Although speculative, Muller cell abnormalities may secondarily affect photoreceptors in eyes with IPT, leading to the deep capillary proliferation.

Hideki Koizumi, Michael J Cooney

The Vitreous, Retina, and Macula Consultants of New York, and the LuEsther T. Mertz Retinal Research Center, Manhattan Eye, Ear, and Throat Hospital, New York, NY, USA

Anita Leys

Department of Ophthalmology, Universitaire Ziekenhuizen, Leuven, Belgium

Richard F Spaide

The Vitreous, Retina, and Macula Consultants of New York, and the LuEsther T. Mertz Retinal Research Center, Manhattan Eye, Ear, and Throat Hospital, New York, NY, USA

Correspondence to: Dr Richard F Spaide, 460 Park Ave, 5th Floor, New York, NY 10022, USA; rickspaide@yahoo.com

doi: 10.1136/bjo.2007.115485

Accepted 1 March 2007

Competing interests: The authors have no proprietary interest in any aspect of this study.

References

- Mansour AM, Schachat A. Foveal avascular zone in idiopathic juxtafoveal telangiectasia. *Ophthalmologica* 1993;**207**:9–12.

telangiectasis in three-dimensional optical coherence tomography. *Am J Ophthalmol* 2006;**142**:340–3.

- Gaudric A, Ducos de Lahitte G, Cohen SY, et al. Optical coherence tomography in group 2A idiopathic juxtafoveal retinal telangiectasis. *Arch Ophthalmol* 2006;**124**:1410–9.
- Jablonski MM, Iannaccone A. Targeted disruption of Muller cell metabolism induces photoreceptor dysmorphogenesis. *Glia* 2000;**32**:192–204.

Expression of hypoxia-inducible factor 1 α and 2 α in choroidal neovascular membranes associated with age-related macular degeneration

Hypoxia-inducible factors (HIF-1 α and HIF-2 α) play pivotal roles in angiogenesis. However, their involvement in choroidal neovascular membranes (CNVMs) is still unknown. This study investigates the distribution of HIF-1 α and HIF-2 α proteins in six CNVMs associated with age-related macular degeneration (AMD). By means of immunohistochemical analysis, HIF-1 α and HIF-2 α were detected in 5 and 6 eyes, respectively. Endothelial cells and macrophages were immunostained by both HIF-1 α and HIF-2 α antibodies, whereas no staining was observed in retinal pigment epithelial (RPE) cells. Our study raises the possibility that HIF-1 α and HIF-2 α are involved in CNV formation.

HIF-1 α and HIF-2 α are transcription factors that transactivate the expression of pro-angiogenic genes in response to hypoxic conditions, and play important roles in vasculogenesis and angiogenesis.^{1,2} HIF-1 α is increased in ischaemic retina, subsequently upregulating the expression of vascular endothelial growth factor (VEGF).³ HIF-2 α exerts pro-angiogenic functions in retinopathy of prematurity, presumably by upregulating the expression of a potent angiogenic factor, erythropoietin.⁴ However, to the best of our knowledge, there has been no study investigating the expression of HIF proteins in human CNVMs. In this study, we performed immunohistochemical analysis to investigate the distribution of HIF proteins in CNVMs.

Specimens were obtained from 6 eyes of 6 AMD patients (aged 65–86 years). Informed consent for the use of excised tissue was obtained from all patients. All procedures followed the tenets of the Declaration of Helsinki, and Institutional Review Board approval was obtained for the study. Between January 2003 and September 2004, submacular surgery was performed according to the technique described previously.⁵ Fluorescein angiography was used to classify the CNV type.⁶ Clinical characteristics of all patients are presented in table 1.

- de Crechcio G, Alfieri MC, Cennamo G, et al. Congenital macular macrovessels. *Graefes Arch Clin Exp Ophthalmol* 2006;**244**:1183–7.
- Provis JM, Sandercoe T, Hendrickson AE. Astrocytes and blood vessels define the foveal rim during primate retinal development. *Invest Ophthalmol Vis Sci* 2000;**41**:2827–36.
- Provis JM. Development of the primate retinal vasculature. *Prog Retin Eye Res* 2001;**20**:799–821.
- Stone J, Ilin A, Alon T, et al. Development of retinal vasculature is mediated by hypoxia-induced vascular endothelial growth factor (VEGF) expression by neuroglia. *J Neurosci* 1995;**15**:4738–47.
- Koizumi H, Slakter JS, Spaide RF. Full-thickness macular hole formation in idiopathic parafoveal telangiectasis. *Retina* 2007;**27**:473–6.
- Yamada E. Some structural features of the fovea centralis in the human retina. *Arch Ophthalmol* 1969;**82**:151–9.
- Koizumi H, Iida T, Maruko I. Morphologic features of group 2A idiopathic juxtafoveal retinal

Table 1 Clinical characteristics

Eye	Age	Sex	Affected eye	CNV type ^a classification	CNVM size*
1	80	M	R	Classic	1.5
2	79	F	L	Predominantly classic	0.8
3	79	F	L	Classic	1.5
4	65	M	L	Classic	1.0
5	86	M	R	Classic	1.3
6	83	F	L	Classic	1.0

M, Male; F, Female; R, right; L, left

CNV, choroidal neovascularization; CNVM, choroidal neovascular membrane

*in disc diameter