

Size of the neuroretinal rim and optic cup and their correlations with ocular and general parameters in adult Chinese: the Beijing eye study

Liang Xu, Yaxing Wang, Hua Yang, Li Zhang, Jost B Jonas

Br J Ophthalmol 2007;**91**:1616–1619. doi: 10.1136/bjo.2007.121509

Aim: To measure the size of the neuroretinal rim, the major variable in the quantitative analysis of the optic nerve head, and its correlations in adult Chinese in a population based setting.

Methods: The Beijing eye study—a population based, cross sectional cohort study—included 4439 subjects from among 5324 of age of 40+ years invited to participate (response rate 83.4%). This study included a random sample of 781 subjects with normal intraocular pressure (IOP), normal visual fields, and a normal optic nerve head; and a random sample of 84 subjects with an IOP >21 mm Hg. Colour optic disc photographs (30°) were examined morphometrically.

Results: In the normal group, the mean (SD) neuroretinal rim area was 1.70 (0.30) mm². It was significantly correlated with optic disc area (rim area = 0.43 * disc area + 0.67; p < 0.001). It was not significantly associated with age, sex, or a known diagnoses of diabetes mellitus, arterial hypertension or hypotension, hyperlipidaemia, coronary heart disease, or cerebral haemorrhage.

Conclusions: In adult Chinese, the neuroretinal rim area measures 1.70 (0.30) mm² on optic disc photographs. It is statistically independent of age. Compared with data from studies in Western countries, the neuroretinal rim is larger in adult Chinese than in adult white populations, corresponding to a larger optic disc size in the Chinese.

The neuroretinal rim of the optic nerve head is the main target in the quantitative analysis of the optic nerve to detect and monitor glaucomatous optic neuropathy.^{1–2} Based on the early studies by Airaksinen *et al*, previous investigations have shown that the rim area is correlated with the disc size; that it decreases in glaucoma; and that the pattern of glaucomatous rim loss may be influenced by the position of the central retinal vessel trunk.^{1–14} Most of these studies were hospital based investigations, while population based studies—particularly in the Chinese population from mainland China—have not usually been focused on the characteristics of the neuroretinal rim.^{10–12} It was therefore the purpose of the present study to assess the size and shape of the neuroretinal rim and its associations in an epidemiological study in mainland China.

METHODS

The Beijing eye study is a population based study in Northern China as described in detail previously.^{15–19} The medical ethics committee of the Beijing Tongren Eye Hospital approved the study protocol and all participants gave their informed consent. In all, 4439 individuals (2505 women) participated in the study (response rate 83.4%). Colour photographs of the optic disc were taken and assessed. The disc photographs were digitised

and the disc structures were measured by outlining their borders. We measured the optic disc, optic cup, peripapillary scleral ring, and the alpha and beta zones of the peripapillary atrophy border on the computer screen. The optic disc was defined as the whole area inside the peripapillary scleral ring. The method has been described in detail previously.^{13–19} The measurements were made by a single examiner (YW) after a training period in which optic disc photographs of about 900 subjects were examined and discussed with two glaucoma specialists (LX, JBJ). Magnification of the eye by the optic media was corrected for by Littmann's method, taking into account the refractive error.²⁰ Refractive error was defined as the spherical equivalent. The anterior corneal curvature radius was set at 7.8 mm, which is the reported to be mean for both Chinese and white populations.²¹ To check the correction of the magnification of the optic disc photographs, including magnification by the fundus camera, the optic discs of 52 eyes were additionally imaged using a confocal laser scanning tomograph (Heidelberg Retina Tomograph HRT; Heidelberg Engineering, Dossenheim, Germany). A comparison of the measurements obtained by planimetry of the digitised optic disc photographs and those made by confocal laser scanning tomography showed that the measurements differed by a linear factor of 1:1.02.¹⁷

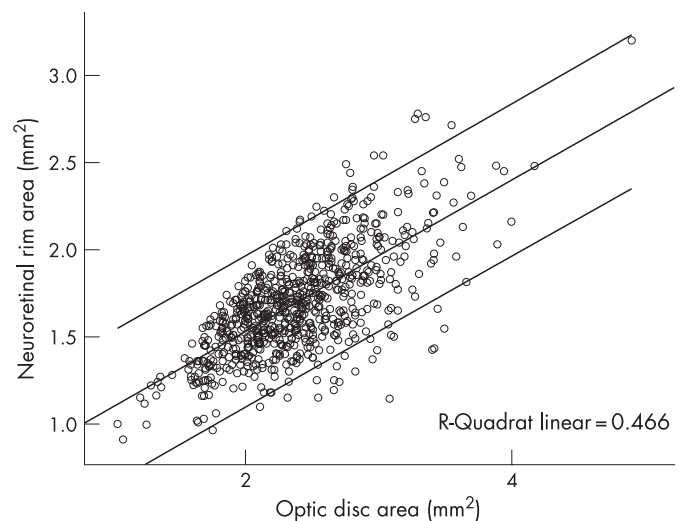


Figure 1 Scattergram showing the correlation between neuroretinal rim area and optic disc area in 781 subjects from the Beijing eye study with normal intraocular pressure, normal visual fields, and normal appearance of the optic nerve head. The equation of the regression line was $\text{neuroretinal rim area} = 0.43 * \text{optic disc area} + 0.67 \text{ mm}^2$ ($p < 0.001$; correlation coefficient $r = 0.68$; areas in mm²). If the point in the right upper corner of the scattergram was removed, the correlation maintained its statistical significance without major changes.

In the present study we examined randomly selected eyes in which measurements of the neuroretinal rim were obtained. The total study population was divided into eyes with normal intraocular pressure, normal visual fields, and an unremarkable appearance of the optic nerve head, and those with an intraocular pressure greater than 21 mm Hg. For the latter group, neither the appearance of the optic nerve head nor the perimetric results were taken into account. Eyes with a myopic refractive error greater than -8 diopters were excluded owing to the secondary enlargement of optic disc in high myopia.^{13 22} Only one randomly selected eye per subject was taken for statistical analysis.

RESULTS

Of the 4439 individuals, optic disc photographs from 865 subjects (865 eyes) were entered into the statistical analysis. The study population was divided into 781 randomly selected eyes (781 subjects), which had a normal intraocular pressure, normal visual fields, and a normal appearance of the optic nerve head; and 84 randomly selected eyes (84 subjects) with an increased intraocular pressure of more than 21 mm Hg. Mean (SD) refractive error was -0.10 (1.46) diopters (-8.0 to $+6.38$ diopters), mean optic disc area was 2.38 (0.48) mm², and mean optic cup area measured 0.68 (0.34) mm². The subjects randomly selected to be included into the present study and the subjects not included in this investigation did not vary significantly in age ($p = 0.30$), sex ($p = 0.66$), refractive error ($p = 0.83$), or best corrected visual acuity ($p = 0.84$).

In the normal group, mean rim area measured 1.70 (0.30) mm² (median = 1.67 mm²; range, 0.91 to 3.20 mm²). It was significantly correlated with optic disc area, with a regression line equation $neuroretinal\ rim\ area = 0.43 * optic\ disc\ area + 0.67$ mm² ($p < 0.001$; correlation coefficient $r = 0.68$; areas in mm²) (fig 1). Neuroretinal rim area was not significantly associated with age, sex, or the known diagnosis of diabetes mellitus, arterial hypertension, arterial hypotension, hyperlipidaemia, coronary heart disease, or cerebral haemorrhage (table 1). Parallel to an increase with disc size, rim area increased with myopic refractive error ($p < 0.001$; $r = 0.24$; 95% confidence interval (CI), -0.063 to -0.035). If the rim area was corrected for its dependence on disc size using the formula $corrected\ rim\ area = rim\ area + (2.34\ mm^2 - disc\ area) * 0.43$ (fig 2), the corrected rim area was still slightly correlated with refractive

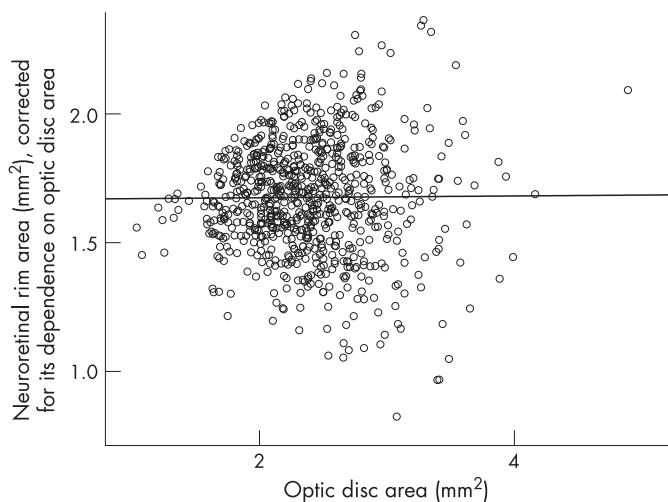


Figure 2 Scattergram showing the relation between optic disc area and neuroretinal rim area corrected for its dependence on optic disc size in 781 subjects of the Beijing eye study with normal intraocular pressure, normal visual fields, and with an age of 40+ years; the relation is not significant ($p = 0.83$).

Table 1 Correlations between neuroretinal rim area, demographic data, and known diagnosis of systemic diseases in 781 normal eyes (781 subjects) with normal intraocular pressure and normal visual fields

	p Value	95% CI
Age	0.06 (NS)	-0.004 to 0.000
Sex	0.84 (NS)	-0.046 to 0.038
Known diagnosis of:		
Arterial hypertension	0.75 (NS)	-0.05 to 0.06
Arterial hypotension	0.27 (NS)	-0.07 to 0.23
Diabetes mellitus	0.31 (NS)	-0.06 to 0.18
Hyperlipidaemia	0.60 (NS)	-0.05 to 0.08
CHD	0.46 (NS)	-0.05 to 0.11
Cerebral haemorrhage	0.25 (NS)	-0.19 to 0.05

CHD, coronary heart disease; CI, confidence interval.

error (correlation coefficient $r^2 = 0.01$; $p = 0.003$). Rim area did not vary significantly ($p = 0.84$) between women (1.70 (0.30) mm²) and men (1.69 (0.31) mm²). The rim area was not associated with age ($r = -0.07$; $p = 0.06$; 95% CI, -0.004 to 0.00) or intraocular pressure ($r = -0.02$; $p = 0.54$; 95% CI, -0.01 to 0.006).

Mean optic disc area was 2.38 (0.48) mm² (range 1.03 to 4.90), and mean optic cup size measured 0.68 (0.34) mm² (0.00 to 2.08) (fig 3). Optic cup area was significantly correlated with disc size (regression line: $optic\ cup\ area = 0.54 * optic\ disc\ area - 0.61$ mm² ($p < 0.001$; $r = 0.75$; areas in mm²) (fig 4).

In the group with raised intraocular pressure, the mean rim area (1.42 (0.44) mm²; median = 1.45 mm²; range 0.40 to 2.13 mm²) was significantly smaller than in the normal study group ($p < 0.001$; 95% CI, 0.23 to 0.41). Correspondingly, mean cup area (1.02 (0.58) mm²) was significantly larger in the hypertensive group ($p < 0.001$; 95% CI, -0.54 to -0.29), while the mean disc area (2.46 (0.50) mm²) did not vary between the normotensive group and the hypertensive group ($p = 0.05$; 95% CI, -0.21 to 0.00). Mean refractive error (-0.42 (1.87) diopters; median = 0.00 diopters; range -7.75 to $+3.38$ diopters) did not

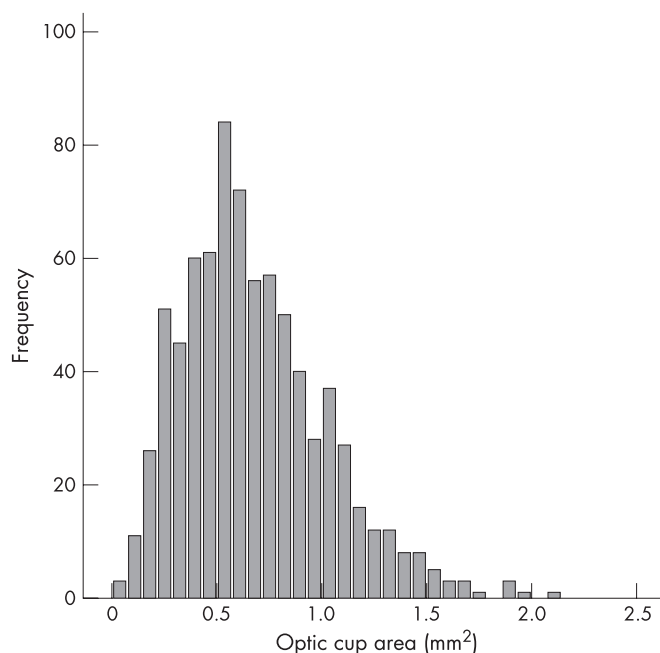


Figure 3 Histogram showing the distribution of the optic cup area in 781 subjects of the Beijing eye study with normal intraocular pressure, normal visual fields, and normal appearance of the optic nerve head.

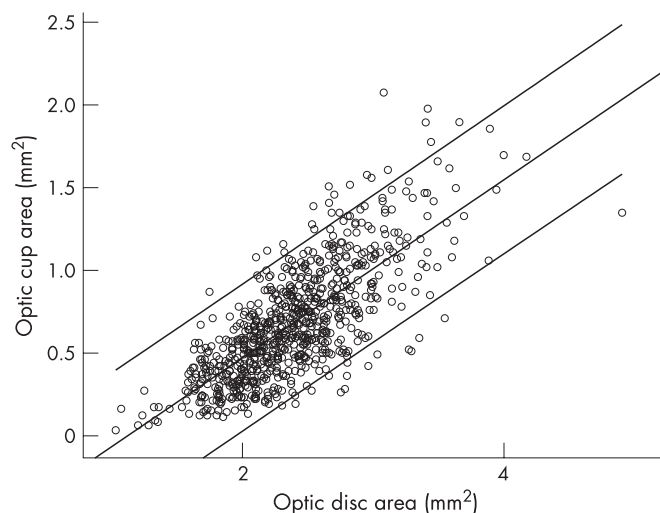


Figure 4 Scattergram showing the correlation between optic cup area and optic disc area in 781 subjects of the Beijing eye study with normal intraocular pressure, normal visual fields, and normal appearance of the optic nerve head. Equation of the regression line: $optic\ cup\ area = 0.54 * optic\ disc\ area - 0.61\ mm^2$ ($p < 0.001$; correlation coefficient $r = 0.75$).

vary between the two groups ($p = 0.07$; 95% CI, -0.03 to 0.79). Combining both study groups, the neuroretinal rim area decreased significantly with intraocular pressure (fig 5), uncorrected and corrected for its dependence on optic disc size ($p < 0.001$; $r = -0.34$; 95% CI, -0.023 to -0.015 ; regression line: $neuroretinal\ rim\ area\ (mm^2) = -0.019 * intraocular\ pressure\ (mm\ Hg) + 1.96\ mm^2$).

DISCUSSION

The results suggest that the neuroretinal rim is larger in an adult Chinese population than in adult white (europid) populations if the data of the present study are compared with the findings of studies in Western countries.^{1-4 10 12 23 24} Reasons may be that in Chinese as well as in white populations the neuroretinal rim area is correlated with the optic disc size, and that the optic disc is larger in the Chinese.^{1-4 10 12 23 24} Correspondingly, the optic cup was larger in adult Chinese subjects than in white populations if the optic cup measurements obtained in the present investigation are compared with results of studies undertaken in Western countries. This leads to a relatively low percentage of optic discs without cupping in the Chinese population compared with Western population groups (fig 3).

The neuroretinal rim size was not constant but showed interindividual variability of 0.91 to $3.20\ mm^2$, or 1 to 3.5 . This relatively high variability may explain why the neuroretinal rim area as single parameter has not been shown to have high diagnostic precision for separating normal eyes from eyes with glaucomatous optic nerve damage.¹³ The rim area was, however, significantly correlated with optic disc area (fig 1), so that the interindividual variability may partially explain the variability in rim area. Using the equation of the regression line between rim area and disc area and calculating for each optic disc size measurement the 95% confidence interval of neuroretinal rim area may increase the diagnostic precision of the neuroretinal rim area for detecting glaucoma.

As already discussed for white populations, the correlation between rim area and disc area may generally correspond to the positive correlation between optic disc size, optic nerve fibre count, and the number and total area of the lamina cribrosa pores.¹³ It remains unclear whether this points towards a greater anatomical reserve capacity in eyes with large optic discs compared with eyes with small optic discs. Although the

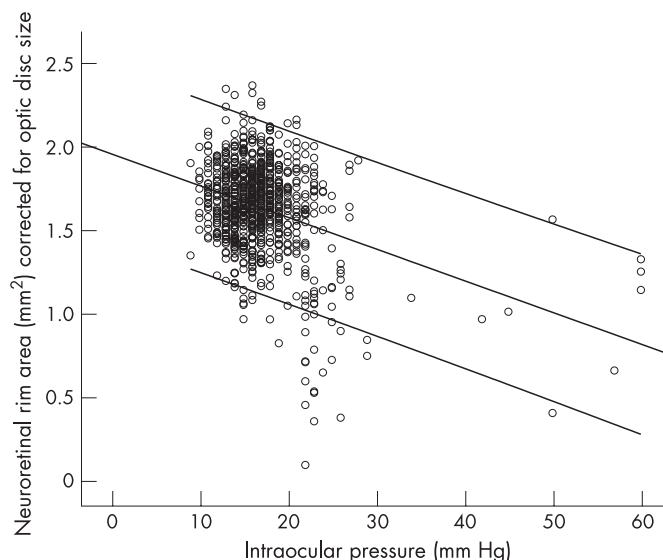


Figure 5 Scattergram showing the relation between neuroretinal rim area corrected for its dependence on optic disc size and intraocular pressure in 865 Chinese subjects aged 40+ years from the Beijing eye study. Equation of the regression line: $neuroretinal\ rim\ area\ (mm^2) = -0.019 * intraocular\ pressure\ (mm\ Hg) + 1.96\ mm^2$.

histomorphometric studies have been carried out on eyes from white populations, one may assume that the reasons for the interindividual size variability of the rim area may be a different nerve fibre count, a different relation between embryologically formed and regressed retinal ganglion cell axons,²⁵ different density of nerve fibres within the optic disc, a different lamina cribrosa architecture, different diameters of retinal ganglion cell axons, a different proportion of glial cells on the whole intrapapillary tissue, or other factors.¹³

Conclusions

In adult Chinese people living in Greater Beijing, the neuroretinal rim shows a similar interindividual variability and correlations with ocular and general parameters as in white populations. Compared with people of European origin, the Chinese have a larger neuroretinal rim owing to a larger optic disc. These data may be helpful for the quantitative and qualitative diagnosis of optic nerve diseases, particularly glaucoma.

ACKNOWLEDGEMENT

Supported by the National Key Laboratory Fund.

Authors' affiliations

L Xu, Y Wang, H Yang, L Zhang, Beijing Institute of Ophthalmology, Beijing Tongren Hospital, Capital University of Medical Science, Beijing, China

J B Jonas, Department of Ophthalmology, Medical Faculty Mannheim of the Ruprecht-Karls-University Heidelberg, Germany

Competing interests: None declared.

Correspondence to: Professor Jost B Jonas, Beijing Institute of Ophthalmology, 17 Hougou Street, Chong Wen Men, 100005 Beijing, China; jost.jonas@augen.ma.uni-heidelberg.de

Accepted 1 June 2007

Published Online First 27 June 2007

REFERENCES

- 1 Betz P, Camps F, Collignon-Brach C, et al. Photographie stéréoscopique et photogrammétrie de l'excavation physiologique de la papille. *J Fr Ophthalmol* 1981;4:193-203.

- 2 **Airaksinen PJ**, Drance SM. Neuroretinal rim area and retinal nerve fiber layer in glaucoma. *Arch Ophthalmol* 1985;**103**:203-4.
- 3 **Airaksinen PJ**, Drance SM, Schulzer M. Neuroretinal rim area in early glaucoma. *Am J Ophthalmol* 1985;**99**:1-4.
- 4 **Britton RJ**, Drance SM, Schulzer MD, *et al*. The area of the neuroretinal rim of the optic nerve in normal eyes. *Am J Ophthalmol* 1987;**103**:497-504.
- 5 **Caprioli J**, Miller JM. Optic disc rim area is related to disc size in normal subjects. *Arch Ophthalmol* 1987;**105**:1683-5.
- 6 **Jonas JB**, Gusek GC, Naumann GO. Optic disc, cup and neuroretinal rim size, configuration, and correlations in normal eyes. *Invest Ophthalmol Vis Sci*. 1988;**29**:1151-8; Correction, 1991;**32**:1893.
- 7 **Jonas JB**, Gusek GC, Naumann GO. Optic disc morphometry in chronic primary open-angle glaucoma. I. Morphometric intrapapillary characteristics. *Graefes Arch Clin Exp Ophthalmol* 1988;**226**:522-30.
- 8 **Montgomery D**. Measurement of optic disc and neuroretinal rim areas in normal and glaucomatous eyes. *Ophthalmology* 1991;**98**:50-9.
- 9 **Caprioli J**. Discrimination between normal and glaucomatous eyes. *Invest Ophthalmol Vis Sci* 1992;**33**:153-9.
- 10 **Varma R**, Tielsch JM, Quigley HA, *et al*. Race-, age-, gender-, and refractive error-related differences in the normal optic disc. *Arch Ophthalmol* 1994;**112**:1068-76.
- 11 **Garway-Heath DF**, Wollstein G, Hitchings RA. Aging changes of the optic nerve head in relation to open angle glaucoma. *Br J Ophthalmol* 1998;**81**:840-5.
- 12 **Ramrattan RS**, Wolfs RCW, Hofmann A, *et al*. Determinants of optic disk characteristics in a general population. The Rotterdam Study. *Ophthalmology* 1999;**106**:1588-96.
- 13 **Jonas JB**, Budde WM, Panda-Jonas S. Ophthalmoscopic evaluation of the optic nerve head. *Surv Ophthalmol* 1999;**43**:293-320.
- 14 **Jonas JB**, Budde WM, Németh J, *et al*. Central retinal vessel trunk exit and location of glaucomatous parapapillary atrophy in glaucoma. *Ophthalmology* 2001;**108**:1059-64.
- 15 **Xu L**, Li J, Cui T, *et al*. Refractive error in urban and rural adult Chinese in Beijing. *Ophthalmology* 2005;**112**:1676-83.
- 16 **Xu L**, Li J, Zheng Y, *et al*. Intraocular pressure in Northern China in an urban and rural population. The Beijing Eye Study. *Am J Ophthalmol* 2005;**140**:913-15.
- 17 **Wang Y**, Xu L, Zhang L, *et al*. Optic disc size in a population-based study in Northern China. The Beijing Eye Study. *Br J Ophthalmol* 2006;**90**:353-6.
- 18 **Wang Y**, Xu L, Hu L, *et al*. Frequency of optic disc hemorrhages in adult Chinese in rural and urban China. The Beijing Eye Study. *Am J Ophthalmol* 2006;**142**:241-6.
- 19 **Xu L**, Wang Y, Wang S, *et al*. High myopia and glaucoma susceptibility. The Beijing Eye Study. *Ophthalmology* 2007;**114**:216-20.
- 20 **Littmann H**. Zur Bestimmung der wahren Größe eines Objektes auf dem Hintergrund des lebenden Auges. *Klin Monatsbl Augenheilkd* 1982;**180**:286-9.
- 21 **Cheung SW**, Cho P, Douthwaite W. Corneal shape of Hong Kong-Chinese. *Ophthalmic Physiol Opt* 2000;**20**:119-25.
- 22 **Xu L**, Li Y, Wang S, *et al*. Characteristics of highly myopic eyes. The Beijing Eye Study. *Ophthalmology* 2007;**114**:121-6.
- 23 **Healey PR**, Mitchell P. Optic disk size in open-angle glaucoma: the Blue Mountains Eye Study. *Am J Ophthalmol* 1999;**128**:515-17.
- 24 **Chi T**, Ritch R, Stickler D, *et al*. Racial differences in optic nerve head parameters. *Arch Ophthalmol* 1989;**107**:836-9.
- 25 **Provis JM**, van Driel, D, Billson FA, *et al*. Human fetal optic nerve: overproduction and elimination of retinal axons during development. *J Comp Neurol* 1985;**238**:92-110.

Keep up to date: sign up for our alerting services

Find out automatically when an article is published on a specific topic or by a particular author. We can also alert you when an article is cited or if an eLetter or correction is published. You can also choose to be alerted when a new issue is published online [and when we post articles Online First]. Check out the New Content Alerts and Citation tracker from the Online tools section on the home page.